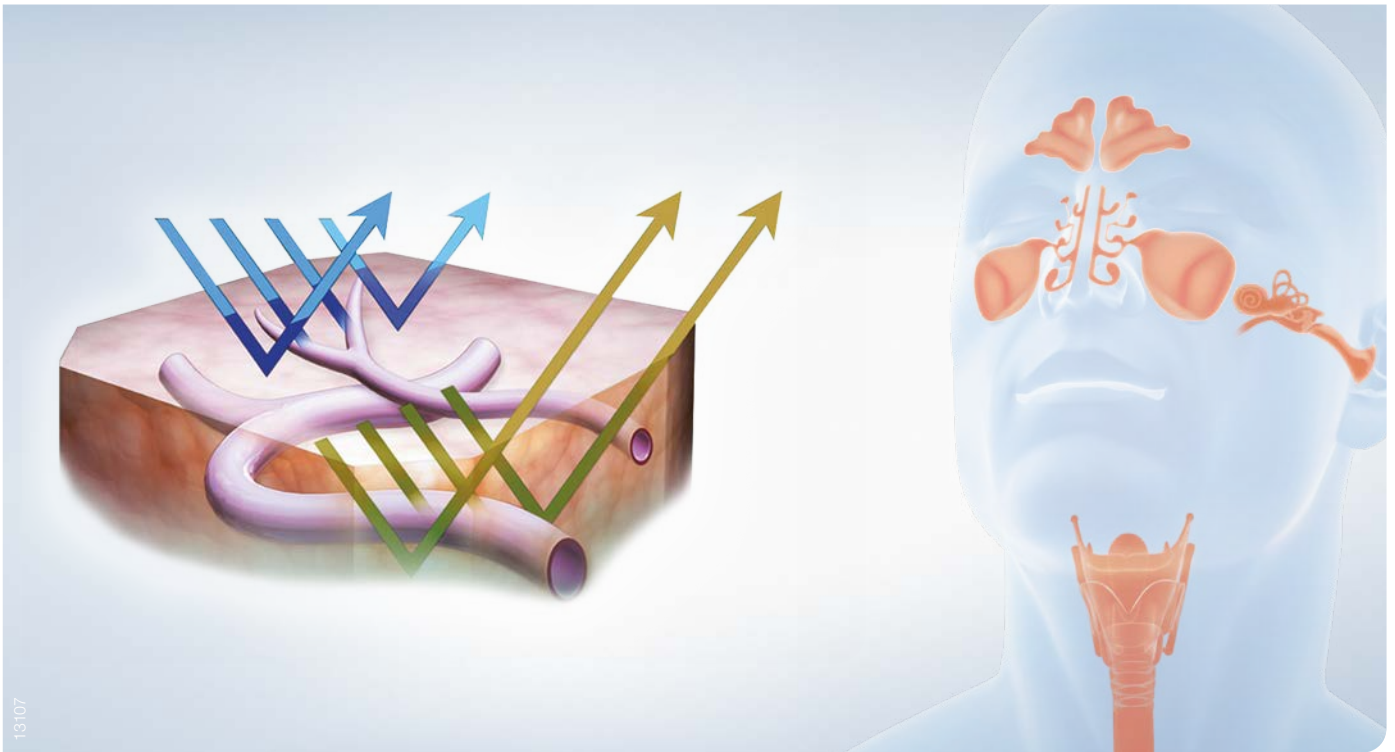


Recommended
by ELS!

NARROW BAND IMAGING IN ENT

Review of Clinical Evidence.



HIGH DEFINITION NARROW BAND IMAGING – TECHNICAL PRINCIPLE

Narrow Band Imaging (NBI)

NBI is an optical image enhancement technology that improves the visibility of vessels and other tissues on the mucosal surface. Narrow-band illumination, which is strongly absorbed by hemoglobin and penetrates only the surface of tissues, is good for enhancing the contrast between the two. As a result, under narrow-band illumination, capillaries within the mucosal surface are displayed in brown on the monitor, while veins in the submucosa are displayed in cyan.

Prospective study proves advantages of NBI

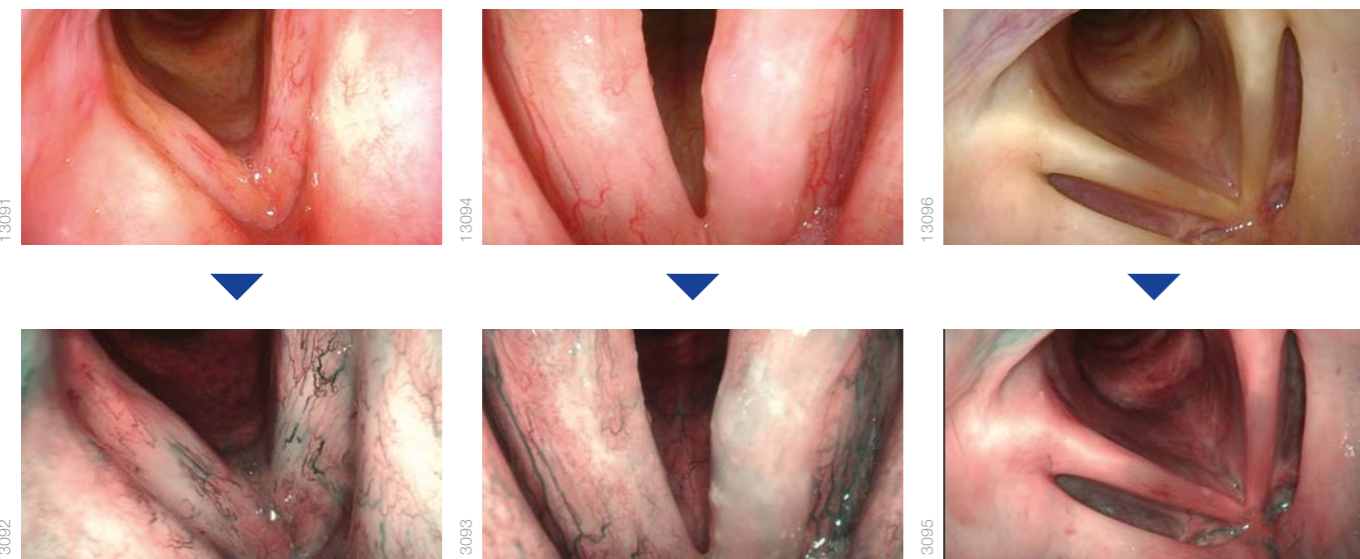
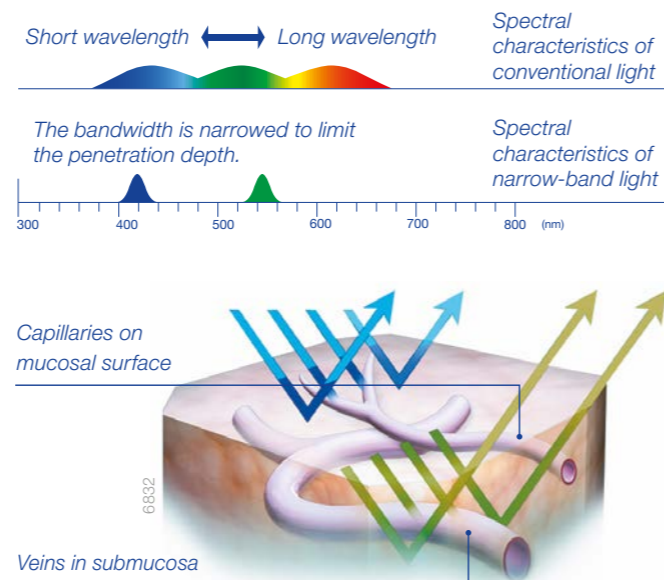
In particular, the combination of HDTV and NBI significantly improves positive and negative predictive rates.

NBI provides better definition of tumor staging and surgical margins in pre- and intra-operative settings. NBI is also valuable in post-operative settings due to its capacity for in early detection of persistences, recurrences, and metachronous tumors.



NBI image on the monitor
Capillaries on mucosal surface displayed in brown and veins in submucosa displayed in cyan.

Penetration depth of light according to wavelength



Narrow Band Imaging - Clinical Advantages:

- The use of NBI enables superior detection of tumors in comparison to conventional white light imaging.*
- The improved visualization of capillary networks possible with NBI allows for analysis of tumor progression.*
- It is possible to identify small tumors using NBI, allowing for detection at an earlier stage.*

* These advantages are proven by studies, which are shown on the following pages.

GUIDELINE RECOMMENDATIONS

1

European Laryngological Society: ELS recommendations for the follow-up of patients treated for laryngeal cancer.

Simo R¹, Bradley P, Chevalier D, Dikkers F, Eckel H, Matar N, Peretti G, Piazza C, Remacle M, Quer M. Eur Arch Otorhinolaryngol. 2014 Sep;271(9):2469-79.

Abstract: It is accepted that the follow-up of patients who had treatment for laryngeal cancer is a fundamental part of their care. The reasons of post-treatment follow-up include evaluation of treatment response, early identification of recurrence, early detection of new primary tumors, monitoring and management of complications, optimization of rehabilitation, promotion of smoking and excessive alcohol cessation, provision of support to patients and their families, patient counseling, and education. Controversies exist in how these aims are achieved. Increasing efforts are being made to rationalize the structure and timing of head and neck cancer follow-up clinics. The aim of this document is to analyze the current evidence for the need to follow up patients who have been treated for LC and provide an up-to-date, evidence-based statement which is meaningful and applicable to all European health care systems. A working group of the Head and Neck Cancer Committee of the ELS was constituted in 2009. A review of the current published literature on the management and follow-up of laryngeal cancer was undertaken, and statements are made based on critical appraisal of the literature and the best current evidence. Category recommendations were based on the Oxford Centre for Evidence-Based Medicine. Statements include: length, frequency, setting, type of health professional, clinical assessment, screening investigations, patient's education, second primary tumors, and mode of treatment considerations, including radiotherapy, chemo-radiation therapy, transoral surgery, and open surgery. It also addresses specific recommendations regarding patients with persistent pain, new imaging techniques, tumor markers, and narrow band imaging.

Summary of Results

NBI can detect 18% more true-positive laryngeal cancer lesions than conventional white light endoscopy. The detection rate is maintained even after radiotherapy or chemoradiotherapy, due to its high accuracy (98%) in differentiating between neoplastic disease and post-RT inflammatory and/or cicatricial changes. NBI, possibly associated with high-definition television technology, **is the most accurate clinical tool for the follow-up of laryngeal cancer.**

¹ Department of Otorhinolaryngology Head and Neck Surgery, Guy's and St Thomas' Hospital NHS Foundation Trust, London, UK, ricard.simo@gstt.nhs.uk.

STUDY ABSTRACT

2

Narrow band imaging and high definition television in the endoscopic evaluation of upper aero-digestive tract cancer.

Piazza C¹, Cocco D, Del Bon F, Mangili S, Nicolai P, Peretti G. Acta Otorhinolaryngol Ital.2011 Apr;31(2):70-5.

Summary: Narrow band imaging and high definition television are recent innovations in upper aero-digestive tract endoscopy. The aim of this prospective, non-randomized, unblinded study was to establish the diagnostic advantage of these procedures in the evaluation of squamous cell cancer arising from various upper aero-digestive tract sites. Between April 2007 and January 2010, 444 patients affected by upper aero-digestive tract squamous cell cancer, or previously treated for it, were evaluated by white light and narrow band imaging ± high definition television endoscopy, both in the pre-/intra-operative setting and during follow-up. Tumor resection was performed taking into account narrow band imaging and high definition television information to obtain histopathologic confirmation of their validity. Endoscopic and pathologic data were subsequently matched to obtain sensitivity, specificity, positive, negative predictive values, and accuracy. Overall, 110 (25%) patients showed adjunctive findings by narrow band imaging ± high definition television when compared to standard white light endoscopy. Of these patients, 98 (89%) received histopathological confirmation. The sensitivity, specificity, positive, negative predictive values, and accuracy for white light-high definition television were 41%, 92%, 87%, 82%, and 67%, for narrow band imaging alone 75%, 87%, 87%, 74%, and 80%, and for narrow band imaging-high definition television 97%, 84%, 88%, 96%, and 92%. The highest diagnostic gain was observed in the oral cavity and oropharynx (25%). Narrow band imaging and high definition television were of value in the definition of superficial tumor extension, and in the detection of synchronous lesions in the pre-/intra-operative settings. These technologies also played an important role during post-treatment surveillance for early detection of persistences, recurrences, and metachronous tumors.

Abstract Summary

- **NBI showed superior sensitivity for identification of upper aero-digestive tract cancer in comparison to white light image (97% vs. 41%).**
- **Tumor categories could be more easily defined when using NBI.**
- **Use of NBI led to a diagnostic gain in 22% of patients in comparison to the white light image.**
- **Detection of tumor recurrence and persistence was improved when NBI was used for screening post-treatment patients.**

¹ Department of Otorhinolaryngology - Head and Neck Surgery, University of Brescia, Italy. ceceplaza@libero.it

STUDY ABSTRACT

3

The diagnostic value of narrow-band imaging for the detection of nasopharyngeal carcinoma.

Yang H¹, Zheng Y, Chen Q, Xiong H, Chen B, Zhang Z, Huang X, Peng J.

ORL J Otorhinolaryngol Relat Spec. 2012;74(5):235-9.

Objectives: To evaluate the diagnostic value of narrow-band imaging (NBI) for the detection of nasopharyngeal carcinoma (NPC).

Study Design: Prospective study.

Setting: Tertiary medical center.

Subjects and Methods: Between December 2009 and June 2010, a total of 1,854 patients were examined by means of an electronic nasopharyngolaryngoscope equipped with conventional white light (WL) and an NBI system. The sensitivity, specificity, and positive/negative predictive values for detecting NPC were calculated and compared.

Results: Of these patients, 62 cases (3.34%) were pathologically confirmed as NPC. The sensitivity, specificity, positive predictive value and negative predictive value for detecting NPC significantly increased from 90.3%, 75.4%, 11.3%, and 99.6% with WL up to 100%, 99.2%, 81.6%, and 100% with NBI, respectively.

Conclusions:

Our findings suggested that NBI endoscopy might serve as an ideal tool in the detection of NPC.

Abstract Summary

- NBI was found to be more sensitive for diagnosing squamous cell carcinoma, with 100% of the 62 pathologically verified cancerous lesions successfully identified, in comparison to the 90.3% identified by using white light imaging ($p < 0.05$).
- Only 14/76 false positives were obtained when using NBI, in contrast to the 440/496 obtained when using white light imaging (PPV: 81.6% vs. 11.3%).
- The enhanced visualization of capillary networks possible with NBI allowed for identification of cancerous lesions less than 5.0 mm in diameter (6/6); none of these were detected when white light imaging was used (0/6).
- NBI showed great potential for detecting cancerous lesions at an extremely early stage in their development.

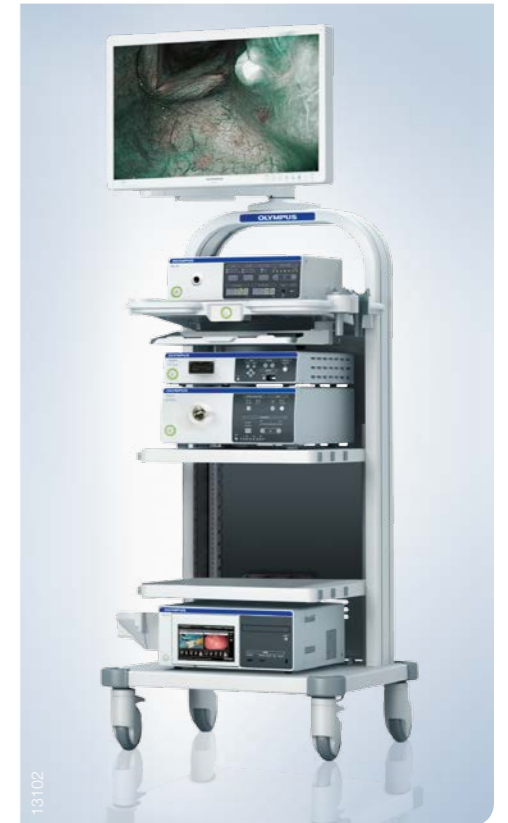¹ Department of Otorhinolaryngology, Head and Neck Surgery, Sun Yat-sen Memorial Hospital, Guangzhou, China.

NARROW BAND IMAGING IN ENT

State-of-the-art imaging techniques in ENT deliver true-to-life image quality in crystal clear detail. The brilliant full HD resolution is the basis for the high accuracy in ENT diagnostic and therapeutic procedures, larynx surgery, laparoscopy, and otoscopy. The innovative Narrow Band Imaging (NBI) technology allows for the enhanced visibility of vessel structures leading to the improved detection of carcinoma *in situ* in the larynx*, as well as saving healthy mucosa due to more precisely defined borders.

VISERA ELITE: the ENT imaging platform

- Advanced full HD for improved color reproduction
- For use with a full variety of rigid and flexible ENT endoscopes
- Increased light output (+20% brightness compared to prior generation) for advanced Narrow Band Imaging (NBI) suitable for detection of small lesions in the oral cavity and larynx
- With stroboscopy light source (StrobeLED)
- Versatile platform to be shared with multiple surgical specialities



VISERA ELITE: supports the ENT physician in all procedural needs



* Piazza C, Cocco D, De Benedetto L, et al. Narrow band imaging and high definition television in the assessment of laryngeal cancer: a prospective study on 279 patients. Eur Arch Otorhinolaryngol. 2010 Mar;267(3):409-14

NARROW BAND IMAGING IN ENT



E0492289 · 2.000 · 06/15 · PR · HB

Specifications, design, and accessories are subject to change without any notice or obligation on the part of the manufacturer.

OLYMPUS

OLYMPUS EUROPA SE & CO. KG

Postbox 10 49 08, 20034 Hamburg, Germany
Wendenstrasse 14-18, 20097 Hamburg, Germany
Phone: +49 40 23773-0, Fax: +49 40 233765
www.olympus-europa.com